

In the United States Court of Federal Claims

OFFICE OF SPECIAL MASTERS

Filed: January 5, 2021

\*\*\*\*\*

SHANNA SALAZAR,	*	PUBLISHED
	*	
Petitioner,	*	No. 15-817V
	*	
v.	*	Special Master Nora Beth Dorsey
	*	
SECRETARY OF HEALTH	*	Ruling on Entitlement; Causation-in-Fact;
AND HUMAN SERVICES,	*	Influenza (“Flu”) Vaccine; Right-Sided
	*	Ulnar Neuropathy.
Respondent.	*	
	*	

\*\*\*\*\*

Max J. Muller, Muller Brazil, LLP, Dresher, PA, for petitioner.  
Lynn C. Schlie, U.S. Department of Justice, Washington, DC, for respondent.

**RULING ON ENTITLEMENT**<sup>1</sup>

**I. INTRODUCTION**

On July 31, 2015, Shanna Salazar (“petitioner”) filed a petition for compensation under the National Vaccine Injury Compensation Program (“Vaccine Act” or “the Program”), 42 U.S.C. § 300aa-10 et seq. (2012).<sup>2</sup> Petitioner alleged that she suffered pain, limited range of motion, limited use, various shoulder injuries, and right ulnar neuropathy as the result of an

<sup>1</sup> The undersigned intends to post this Ruling on the United States Court of Federal Claims’ website. **This means the Ruling will be available to anyone with access to the internet.** In accordance with Vaccine Rule 18(b), petitioner has 14 days to identify and move to redact medical or other information, the disclosure of which would constitute an unwarranted invasion of privacy. If, upon review, the undersigned agrees that the identified material fits within this definition, the undersigned will redact such material from public access. Because this published Ruling contains a reasoned explanation for the action in this case, undersigned is required to post it on the United States Court of Federal Claims’ website in accordance with the E-Government Act of 2002. 44 U.S.C. § 3501 note (2012) (Federal Management and Promotion of Electronic Government Services).

<sup>2</sup> The National Vaccine Injury Compensation Program is set forth in Part 2 of the National Childhood Vaccine Injury Act of 1986, Pub. L. No. 99-660, 100 Stat. 3755, codified as amended, 42 U.S.C. §§ 300aa-10 to -34 (2012). All citations in this Ruling to individual sections of the Vaccine Act are to 42 U.S.C. § 300aa.

influenza (“flu”) vaccination she received on October 2, 2014. Petition at Preamble, ¶¶ 4, 8 (ECF No. 1). Subsequently, petitioner amended her petition to also allege that due to her right upper extremity vaccine injury, she overused her left upper arm, resulting in an injury of left ulnar neuropathy. Amended (“Am.”) Petition, filed Feb. 24, 2020 (ECF No. 113).

After a review of the record as a whole, medical records, expert reports, medical literature, briefing by the parties, and for the reasons set forth below, the undersigned finds that petitioner has established by preponderant evidence that she sustained a right ulnar neuropathy caused by her October 2, 2014 flu vaccination and is thus entitled to compensation for that condition. However, the undersigned denies compensation for petitioner’s left arm injury, as petitioner did not provide preponderant evidence of vaccine causation.

## **II. PROCEDURAL HISTORY**

Petitioner filed her petition on July 31, 2015, alleging that she sustained shoulder injuries caused by a flu vaccine administered to her on October 2, 2014. Petition at Preamble. From August 2015 to July 18, 2016, petitioner filed medical records. Petitioner’s Exhibits (“Pet. Exs.”) 1-14. On November 4, 2016, petitioner submitted a motion to issue subpoena. Pet. Motion (“Mot.”) to Issue Subpoena, filed Nov. 4, 2016 (ECF No. 37). Petitioner filed worker’s compensation documentation on January 5, 2017. Pet. Ex. 15.

On February 22, 2018, petitioner filed an expert report from one of her treating physicians, Dr. Pradeep Chopra. Pet. Ex. 16. Petitioner then filed additional medical records on February 27, 2018. Pet. Exs. 17-21.

On September 12, 2018, respondent filed the Rule 4(c) Report, arguing against compensation. Respondent’s Report (“Resp. Rept.”) at 1 (ECF No. 76). On the same day, respondent filed an expert report from Dr. Vinay Chaudhry with supporting medical literature. Resp. Exs. A-E. On February 26, 2019, petitioner filed an affidavit. Pet. Ex. 22. Thereafter, on March 11, 2019, petitioner filed an expert report from Dr. Lawrence Steinman with supporting medical literature. Pet. Ex. 23.

On March 28, 2019, the undersigned held a Rule 5 status conference. See Rule 5 Order dated Mar. 29, 2019 (ECF No. 85). During the Rule 5 conference, the undersigned opined that based on the weight of the evidence, right ulnar neuropathy was the proper diagnosis. Id. at 1. She also found that the petitioner had proposed two mechanisms for her injury, positioning at the time of vaccination or misguided injection, satisfying Althen Prong One. Id.; see Althen v. Sec’y of Health & Hum. Servs., 418 F.3d 1274, 1278 (Fed. Cir. 2005). Further, the undersigned concluded that petitioner’s vaccination and her injury were linked by a logical sequence of cause and effect. Rule 5 Order at 1. The undersigned also found that based on the medical records, as well as the support offered by Dr. Steinman and petitioner’s treating physicians, the time frame between petitioner’s vaccination and the onset of her right ulnar neuropathy was medically appropriate. Id. at 2. The undersigned encouraged the parties to engage in settlement negotiations. Id.

After the Rule 5 status conference, respondent filed a status report on June 3, 2019 stating respondent was not interested in settlement at that time and requested the parties schedule an entitlement hearing. Resp. Status Rept., filed June 3, 2019 (ECF No. 88). Subsequently, an entitlement hearing was set for March 25 and 26, 2020 in Providence, Rhode Island. See Pre-hearing Order dated Aug. 1, 2019 (ECF No. 91). On October 25, 2019, petitioner filed medical records. Pet. Exs. 24-25. On November 25, 2019, petitioner filed additional medical records and a statement of completion. Pet. Exs. 26-27; Statement of Completion, filed Nov. 25, 2019 (ECF No. 98).

On December 30, 2019, the undersigned issued an order referring the case to Alternative Dispute Resolution (“ADR”). Order Referring Case to ADR dated Dec. 30, 2019 (ECF No. 100). Petitioner filed an affidavit and her pre-hearing submissions on January 24, 2020. Pet. Ex. 28; Pet. Pre-Hearing Brief (“Br.”), filed Jan. 24, 2020 (ECF No. 104). On February 12, 2020, the special master presiding over ADR issued an order removing the case from ADR. Order Removing Case from ADR Process dated Feb. 12, 2020 (ECF No. 105).

On February 13, 2020, petitioner filed a motion to amend the petition caption from Shanna Molina to Shanna Salazar.<sup>3</sup> Pet. Mot. to Amend Caption, filed Feb. 13, 2020 (ECF No. 107). Petitioner’s motion was granted the same day. Order Granting Pet. Mot. to Amend Caption dated Feb. 13, 2020 (ECF No. 109). Petitioner then filed additional medical records and an amended petition on February 20 and 24, 2020. Pet. Exs. 29-30; Am. Petition. In her amended petition, petitioner alleged that that she “developed ulnar neuropathy in her left upper extremity as a result of overuse from the initial right ulnar neuropathy injury.” Am. Petition at 1. Petitioner reiterated the facts supporting her right arm right ulnar neuropathy and asserted additional facts to support her position that she sustained an injury in her left upper arm due to overuse of the left arm due to her right arm injury. See id. at 2-4. Thus, petitioner alleged both right and left ulnar neuropathy as a result of her October 2, 2014 flu vaccination. Id. at 4.

Respondent filed his pre-hearing brief on February 24, 2020. Resp. Pre-Hearing Br., filed Feb. 24, 2020 (ECF No. 119). Petitioner filed updated medical literature on the same day. Pet. Ex. 31. On February 25, 2020, respondent filed a supplemental expert report from Dr. Chaudhry and supporting medical literature. Resp. Exs. G-H.

The undersigned held a status conference on March 12, 2020 because the Federal District Courthouse in Providence, Rhode Island cancelled the entitlement hearing scheduled there for March 25-26, 2020 due to COVID-19 health and safety concerns. See Order dated Mar. 13, 2020 (ECF No. 125). Subsequently, petitioner filed a joint status report indicating that the parties wished to decide entitlement with a Ruling on the Record. Joint Status Rept., filed Mar. 19, 2020 (ECF No. 126).

Petitioner filed a second supplemental expert report from Dr. Steinman on June 18, 2020. Pet. Ex. 32. Petitioner also filed a brief in support of entitlement to damages. Pet. Br. in Support of Entitlement to Damages, filed June 18, 2020 (ECF No. 131). The next day petitioner filed her motion for a Ruling on the Record. Pet. Mot. for Ruling on the Record (“Pet. Mot.”), filed June

---

<sup>3</sup> Petitioner changed her last name due to marriage. Pet. Mot. to Amend Caption.

19, 2020 (ECF No. 132). In her motion for Ruling on the Record, petitioner seeks only compensation for “right ulnar neuropathy caused by the [flu] vaccination administered on October 2, 2014.” Id. at 8.

On August 19, 2020, respondent filed his response to petitioner’s motion. Resp. Response to Pet. Mot. (“Resp. Response”), filed Aug. 19, 2020 (ECF No. 134). In respondent’s response, respondent stated, that while petitioner appears to no longer seek entitlement for her left arm injury “respondent believes that the record is complete with regard to this issue, and this is also an appropriate time for the Court to determine the extent of petitioner’s alleged injury.” Id. at 23. On October 19, 2020, petitioner filed a Reply. Pet. Reply to Resp. Response (“Pet. Reply”), filed Oct. 19, 2020 (ECF No. 135).

The matter is now ripe for adjudication.

### **III. ISSUES TO BE DECIDED**

First, the parties dispute three factual issues: “a) the nature of petitioner’s right arm injury, including the diagnosis of her injury; b) the nature of petitioner’s left arm injury, including the diagnosis of her injury; and c) whether petitioner had a pre-existing cubital tunnel syndrome in her right and/or left arms prior to vaccination.” Joint Pre-Hearing Submissions, filed Feb. 24, 2020, at 1 (ECF No. 115).

As for causation, the parties dispute: “a) whether the flu vaccine administered to petitioner on October 2, 2014, caused petitioner’s alleged right arm injuries; and, b) whether the flu vaccine administered to petitioner on October 2, 2014, caused petitioner’s alleged left arm injuries.” Joint Pre-Hearing Submissions at 2.

Although the parties agreed to the causation issues framed above, in her motion for a Ruling on the Record, and accompanying briefs, petitioner asserts that her vaccination caused a “significant aggravation of previously dormant cubital tunnel syndrome.” Pet. Mot. at 10; Pet. Reply at 4. Respondent asserts that petitioner has raised conflicting theories of causation: “first, that the flu vaccination she received caused her cubital tunnel syndrome, and second, that the flu vaccine she received significantly aggravated her ‘previously dormant’ cubital tunnel syndrome.” Resp. Response at 11. Respondent further asserts that petitioner is not entitled to compensation for her alleged left arm overuse injury, and asks the Court to adjudicate this issue. Resp. Response at 23.

### **IV. ULNAR NERVE INJURY AND CUBITAL TUNNEL SYNDROME**

#### **A. Ulnar Nerve Injuries Caused by Injection**

The ulnar nerve runs from the “medial cord of the brachial plexus formed by C8 and T1 spinal roots,” down the arm to the hand.<sup>4</sup> Pet. Ex. 23.1 at 4. The nerve innervates muscles that move the wrist, hand, and fingers and “provides sensory innervation” to parts of the hand. *Id.* While injection related injuries to the ulnar nerve are rare, they have been reported in the literature. Kim et. al. studied 645 patients who had ulnar nerve injuries and found that two were caused by injection. *Id.* Geiringer and Leonard reported two cases of ulnar injury after the same nurse administered vaccinations to two different patients, calling into question whether the nurse’s injection technique was the cause of the injuries.<sup>5</sup> Pet. Ex. 23.2 at 1. When administering the vaccinations, the nurse directed the patients to place their hands on their hips and internally rotate their arms.” *Id.* at 2. “Both patients were injected on the left, [and] the nurse [wa]s right handed.” *Id.* Geiringer and Leonard opined that when “[c]ombined with a ‘sidearm’ delivery, this positioning likely facilitated missing the deltoid completely, skirting medial . . . and entering the medial-lying neurovascular bundle . . . [where] the ulnar nerve is susceptible.” *Id.* An ulnar nerve injury was also described by Salanga and Hahn<sup>6</sup> after a vaccination administered by jet injection in a petite patient with “small muscle mass.” Pet. Ex. 23.1 at 4.

The probable path of the vaccination needle described above by Geiringer and Leonard is described in their illustration below.

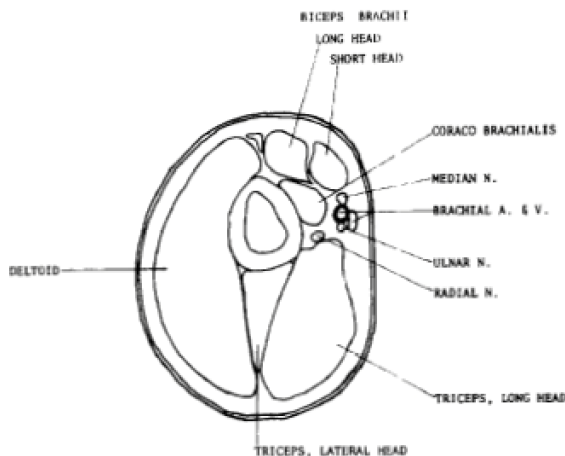


Fig 1—Cross-section of the arm at the level of the deltoid.

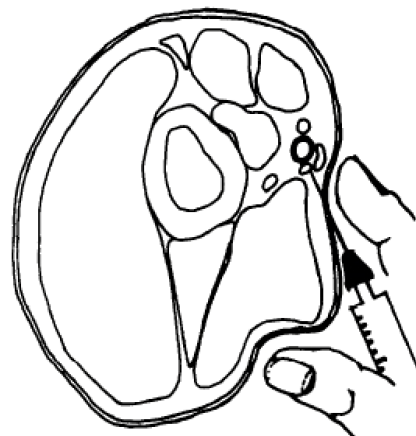


Fig 3—Probable path of needle using improper technique of fig 2.

Pain is the most common symptom of ulnar nerve injury caused by injection. Pet. Ex. 23.1 at 4. Other symptoms “include numbness, paresthesias, and other sensory disturbances.”

<sup>4</sup> Hyun Kim et al., Upper Limb Nerve Injuries Caused by Intramuscular Injection or Routine Venipuncture, 12 *Anesthesiology & Pain Med.* 103 (2017).

<sup>5</sup> Steven Geiringer & James Leonard, Jr., Injection-Related Ulnar Neuropathy, 70 *Archives Physical Med. Rehab.* 705 (1989).

<sup>6</sup> V.D. Salanga & J.F. Hahn, Traumatic Ulnar Neuropathy from Jet Injection: Case Report, 19 *J. Trauma* 283 (1979). This article not filed into evidence by the parties, but referenced by Kim et al.

Id. There may be “weakness of finger abduction and adduction, fourth and fifth finger flexion, wrist adduction and wrist flexion.” Id. The clinical course after “needle-related nerve injury [may] range from transient minor pain to severe sensory disturbance.” Id. at 6. One study showed that most patients have a full recovery with some experiencing residual mild numbness. Id. However, in another study, “21.6% of patients suffered pain/sensory changes more than 1 year.” Id. Axonal regeneration occurs after nerve injury and symptoms usually improve over time. Id.

## **B. Cubital Tunnel Syndrome**

Cubital tunnel syndrome also occurs as a result of injury to the ulnar nerve, however, it is usually due to “compression and traction on the ulnar nerve” at the elbow.<sup>7</sup> Resp. Ex. D at 1.<sup>8</sup> The area around the elbow has a number of structures that can cause compression of the ulnar nerve, including connective tissue, ligaments, and the cubital tunnel itself. Id. The cubital tunnel is comprised of connective tissue, and made up of by the medial epicondyle (bony bump at the bottom of the humerus on the medial side of the elbow), the elbow joint, and the medial collateral ligament (which unites the humerus to the ulna). Id. at 1-2. The roof of the tunnel is formed by an aponeurosis, or fibrous tissue, that attaches muscles to bone. Pet. Ex. 31 at 2.<sup>9</sup> When the elbow is flexed, there is a significant decrease in the size of the canal through which the ulnar nerve passes. Id.; Resp. Ex. D at 2. Normal range of motion of the elbow joint subjects the ulnar nerve to “compression, traction, and frictional forces.” Pet. Ex. 31 at 2.

Cubital tunnel syndrome is thought to be multi-factorial, caused by repetitive motion, prolonged flexion, or direct compression of the ulnar nerve. Pet. Ex. 31 at 1. Onset is generally insidious, especially when caused by repetitive motion and activities. Id. “There are numerous other causes of ulnar neuropathy at the elbow.” Id. at 4. These include “osteoarthritis, rheumatoid arthritis[,] . . . or trauma to the nerve.” Id. In some persons, the ulnar nerve may become subluxed, or displaced, out of the retro epicondylar groove, the notch in the elbow that normally houses the nerve, during elbow flexion. Pet. Ex. 30 at 1-2.<sup>10</sup> Research has shown that in “10% to 16% of the healthy population, the ulnar nerve may sublux anterior . . . when the elbow is flexed.” Pet. Ex. 31 at 3.

---

<sup>7</sup> While ulnar nerve injury may also be referred to as cubital tunnel syndrome, the undersigned will use the phrase ulnar nerve injury or ulnar neuropathy throughout this ruling. The phrase cubital tunnel syndrome will be used when citing to medical records, medical literature, or expert reports that refer to that phrase.

<sup>8</sup> Jonathan Robert Staples & Ryan Calfee, Cubital Tunnel Syndrome: Current Concepts, 25 J. Am. Academy Orthopaedic Surgeons e215 (2017).

<sup>9</sup> David Bozentka, Cubital Tunnel Syndrome Pathophysiology, 351 Clinical Orthopaedics & Related Rsch. 90 (1998).

<sup>10</sup> Jan Michael Lleva & Ke-Vin Chang, Ulnar Neuropathy (StatPearls Publishing, Jan. 2020).

Cubital tunnel syndrome is a clinical diagnosis based on history and physical examination. Resp. Ex. D at 2. Patients may complain of altered sensation of the ring finger and little finger. Id. Pain may be present along the course of the nerve from the elbow into the forearm or hand. Id. Electrodiagnostic studies (“EMGs”) “may inform but do not establish the diagnosis.” Id. at 3. Nonsurgical management consisting of activity modification and splints are recommended for mild to moderate forms of the syndrome, whereas surgical intervention is warranted in more severe cases. Id. at 4.

## V. FACTUAL SUMMARY

### A. Summary of Relevant Facts<sup>11</sup>

On October 2, 2014, petitioner, a registered nurse, received the flu vaccination in her right shoulder at her place of employment, The Miriam Hospital (“Miriam”). See Pet. Ex. 1 at 1; Pet. Ex. 2 at 9. Prior to vaccination, petitioner had no history of neurological or shoulder injuries. Pet. Ex. 3 at 4; Pet. Ex. 22 at 1. At the time of vaccine administration, petitioner was asked to bend her right arm 90 degrees at the elbow, place her hand on her hip, and flex forward. Pet. Ex. 3 at 4; Pet. Ex. 22 at 1. Immediately following the injection, petitioner felt a sensation of pins and needles down her arm and numbness from her elbow to her pinky finger. Pet. Ex. 20 at 64. Petitioner reported her vaccine reaction to employee health personnel and the reaction was documented. Id. The nurse who documented petitioner’s vaccine reaction advised that petitioner could not lift her right arm. Id.

The next day, October 3, 2014, petitioner presented to Dr. Dana Sparhawk at Miriam. Pet. Ex. 20 at 61. Petitioner reported that she received a flu shot the prior day and had experienced “numbness almost immediately.” Id. She also had numbness into her “ulnar forearm and pinky and fourth finger.” Id. Petitioner stated she felt weakness and a burning sensation in her right arm. Id. Dr. Sparhawk noted the flu shot appeared to be given in the appropriate area of the deltoid. Id. Tinel’s<sup>12</sup> test caused tingling “down the ulnar aspect of [petitioner’s] forearm into her fourth and fifth fingers. Tinel’s on the left elbow reveals similar symptoms but much less intense.” Id. Dr. Sparhawk diagnosed petitioner with “neuropraxia of upper extremity.” Id. She concluded that petitioner “had some nerve root irritation as a result of the injection.” Id.

On October 6, 2014, petitioner presented to Dr. Nancy Littell at Rhode Island Hospital complaining of tingling down her right arm since the flu shot. Pet. Ex. 20 at 31. Petitioner complained of pain and weakness in her right arm and numbness of “the ulnar side of forearm” with “pain [that] sometimes radiates upward toward the shoulder.” Id. Petitioner felt “as though

---

<sup>11</sup> Additional factual summaries are set forth in the parties’ briefs. See Pet. Mot.; Resp. Response.

<sup>12</sup> The Tinel sign produces “a tingling sensation in the distal end of a limb when percussion is made over the site of a divided nerve. It indicates a partial lesion or the beginning regeneration of the nerve.” Dorland’s Illustrated Medical Dictionary 1687 (33d ed. 2020). It may also refer to “distal tingling on percussion.” Id.

her arm distal to the elbow [was] being squeezed as if in a tourniquet.” Id. There was no other history of trauma or injury to account for petitioner’s symptoms. Dr. Littell diagnosed petitioner with neuropraxia and neuritis. Id. at 32. She concluded, “I think the nerve was irritated either by the needle or the liquid when she was given the flu shot.” Id. Petitioner had approximately nine follow-up appointments with Dr. Littell between October 9 and December 8, 2014. At her last visit, petitioner continued to have “diminished sensation in the ulnar distribution of the right hand.” Id. at 15.

On October 10, 2014, petitioner presented to the Emergency Department at Rhode Island Hospital for right arm pain, tingling, and numbness. Pet. Ex. 2 at 3-4, 9. Petitioner reported she received a flu shot and “instantly had numbness and shooting pain in her [right] arm down to her 4th/5th digit.” Id. at 9. Weakness was noted in her right hand. Id. at 9-10. Petitioner returned the next day and her physical assessment was “[p]ositive for right arm and right shoulder tenderness; right shoulder stiffness,” “[p]ositive for right neck stiffness,” and “[p]ositive for numbness, tingling, weakness, in right hand, especially in fourth and fifth digits, right elbow, right forearm.” Id. at 12. Dr. Jonathan Schimmel noted the cause of petitioner’s symptoms was unknown, “but some inflammation around one of the nerves in the arm related to the flu shot is possible.” Id. at 7. Flexeril, a muscle relaxant, was prescribed for petitioner’s pain. Id. at 8.

On December 4, 2014, petitioner saw Dr. Petro Karaniasias for a neurology consultation on referral from Dr. Littell. Pet. Ex. 3 at 4. Once again, petitioner repeated the history of an immediate reaction to the flu vaccination and the pain and numbness in her right arm since vaccination. Id. Dr. Karaniasias found “normal range of motion in the right shoulder and elbow[,]” “no muscle atrophy, edema, or discoloration in that extremity[,] . . . a positive Tinel’s sign in the right elbow . . . tenderness to palpation in the right elbow, specifically around the cubital tunnel[,]” and “mild hypoesthesia to pinprick within the right distal ulnar nerve distribution.” Id. at 5. Dr. Karaniasias performed an EMG and found no abnormalities. Id. His diagnosis was right ulnar neuropathy of relatively mild severity of unclear etiology. Id. He stated, “[m]y best guess is that it relates to irritability of the nerve in its segment across the elbow, and the positioning of her arm at the time of the flu shot could be the culprit. I do not feel that the flu shot in itself is directly responsible for the neuropathy.” Id. at 5. He reported that petitioner’s symptoms were improving and should continue to improve. Id. Dr. Karaniasias advised petitioner to avoid repetitive activities that involved her elbow joint such as repetitive lifting. Id. at 6.

On January 22, 2015, petitioner presented to Dr. Thomas McGunigal for a neurophysiologic consultation of her right upper arm. Pet. Ex. 19 at 3. Petitioner complained of right hand numbness that began after her October 2, 2014 flu shot. Id. Petitioner reported pain ranging from a 3/10 to 6/10 depending on activity, with symptoms worse at night. Id. On physical examination Dr. McGunigal noted, “severe tenderness to palpitation of the right ulnar nerve at the right elbow, specifically at the retrocondylar groove and this reproduces and increases the symptoms in her right ulnar hand.” Id. at 4. Dr. McGunigal performed ultrasound of the ulnar nerve that showed enlargement and tenderness. Id. EMG diagnostic testing showed “focal slowing . . . of the right ulnar motor velocity across the elbow localized to the retrocondylar groove . . . [and] relatively prolonged right ulnar F wave.” Id. Dr. McGunigal



diagnosed mild right ulnar neuropathy at the elbow and moderate right ulnar neuropathy at the retrocondylar groove. Id.

Petitioner returned to see Dr. McGunigal on February 5, 2015. Pet. Ex. 19 at 1. At that visit, ultrasound revealed that petitioner's right radial nerve was abnormally enlarged. Id. Dr. McGunigal noted tenderness and increased numbness in the right dorsal hand. Id. Dr. McGunigal diagnosed petitioner with right radial neuropathy at the spiral groove. Id. He noted that this injury had "been reported to occur from misdirected intramuscular deltoid injections. Healing can take up to 1 year of time and may be incomplete." Id.

On April 7, 2015,<sup>13</sup> petitioner presented to Dr. Steven Graff at Pawtucket Orthopedic for right hand surgical consultation on referral by Dr. Sparhawk. Pet. Ex. 5 at 5. At that visit, petitioner "demonstrated full range of motion of the elbow, forearm, wrist and digits, but complained of various vague aches and pains in the extremity at all endpoints and through the actual arc of motion." Id. at 6. Examination of the ulnar nerve revealed a positive Tinel's at the right carpal tunnel "positive to the ulnar distribution." Id. Dr. Graff's diagnosis was "right upper extremity global complaints of pain and numbness that cannot be explained by any anatomically based diagnosis." Id. at 7.

Petitioner returned to Dr. Sparhawk for a follow up on April 8, 2015. Pet. Ex. 5 at 9. Dr. Sparhawk noted petitioner's pain was better and her pain rating had decreased from 4/10 to 2/10. Id. On examination, petitioner had "continued tenderness in the posterior humerus region and pressure on this area cause[d] tingling going into the extensor portion of the forearm into the ulnar aspect of the hand." Id. Tinel's test of the elbow was negative. Id. Sensory exam revealed diminished sensation in the third, fourth, and fifth fingers. Id. Dr. Sparhawk diagnosed petitioner with neuropraxia of right upper extremity. Id.

In her affidavit, petitioner averred that in April 2015, she began having left arm soreness due to overuse of it to compensate for her injuries in the right arm. Pet. Ex. 22 at ¶ 12. In June 2015, petitioner reported to her counselor, Peter Erickson, that she was having soreness in her left arm from overcompensation. Pet. Ex. 7 at 4.

Petitioner had an independent medical examination ("IME")<sup>14</sup> on June 10, 2015 by Dr. Steven G. McCloy. Pet. Ex. 15 (part 2) at 163. After a review of medical records and physical examination, Dr. McCloy diagnosed petitioner with "complication of vaccination, [] resolved . . . causally related to an event at work." Id. Dr. McCloy concluded that her vaccine-related condition had resolved and that she had a co-existing diagnosis of "somatoform disorder." Id. With regard to her left arm symptoms, Dr. McCloy diagnosed petitioner with mild left ulnar neuropathy, "not causally related" to her vaccination. Id. Dr. McCloy opined that there was "no

---

<sup>13</sup> Petitioner's Exhibit 5 states the date May 18, 2015, but is electronically signed on April 7, 2015. The undersigned defers to the parties' apparent agreement that this appointment took place on April 7, as indicated in both parties' briefs.

<sup>14</sup> This IME was done "at the request of . . . Claims Strategies," the Workers' Compensation claims management company for her employer. Pet. Ex. 15 (part 2) at 155.

connection between the shot that [petitioner] received [] and the development of left ulnar neuropathy.” Id. at 164.

On August 6, 2015, petitioner presented to Dr. Pradeep Chopra, at the Interventional Pain Management Center. Pet. Ex. 8 at 1. Dr. Chopra noted petitioner’s history of pain and numbness of the right upper arm since her flu shot on October 2, 2014. Id. On physical exam, petitioner had “tenderness to the right biceps tendon and the bicipital groove” and “dysesthesias to the right ulnar nerve distribution,” as well as the “right deltoid area” and “posterior aspect of her right wrist and hand.” Id. at 3. Dr. Chopra diagnosed petitioner with “right brachial plexus injury to the radial and ulnar nerve at the axilla.” Id. Dr. Chopra suspected that petitioner had right ulnar and right radial neuritis. Id. He recommended that she continue Neurontin and try low dose naltrexone for pain. Id.

Petitioner returned to see Dr. Chopra for a follow up on August 25, 2015. Pet. Ex. 8 at 4. Dr. Chopra documented pain in both arms. Id. Petitioner’s right arm pain was characterized as “neuropathic pain as a result of her flu vaccination.” Id. Dr. Chopra also documented that petitioner had “diffuse musculoskeletal pain to her left upper extremity from overuse” and noted tenderness to her “left medial epicondyle.” Id. Petitioner received a left elbow intra-articular joint injection. Id.

Petitioner continued to see Dr. Chopra for treatment. See Pet. Ex. 12; Pet. Ex. 13 at 1-9. On September 10, 2015, Dr. Chopra noted that petitioner had “left upper pain [] as a result of her repetitive strain injury since she is unable to use her right upper extremity.” Pet. Ex. 13 at 7. On November 23, 2015, Dr. Chopra noted that petitioner had been receiving physical therapy for her left arm and was better. Id. at 1. On March 4, 2016, Dr. Chopra again noted that petitioner had pain in both upper arms. Pet. Ex. 12 at 1.

On March 31, 2016, petitioner presented to Dr. Julia Katarincic at University Orthopaedics for evaluation of bilateral ulnar neuropathies and continued left elbow pain. Pet. Ex. 14 at 6; Pet. Ex. 22 at ¶ 20. Dr. Katarincic diagnosed “bilateral cubital tunnel.” Pet. Ex. 14 at 6. She stated that petitioner had “tried and exhausted conservative therapy with no relief to her symptoms.” Id. Dr. Katarincic discussed petitioner’s surgical options and petitioner elected to proceed with left ulnar nerve transposition surgery. Id.

On April 22, 2016, Dr. Katarincic performed surgical submuscular transposition of petitioner’s left ulnar nerve. Pet. Ex. 17 at 7. During surgery, petitioner’s triceps muscle was noted to be pushing her left ulnar nerve over the epicondyle during flexion. Pet. Ex. 21 at 1-2. Dr. Katarincic observed that “every time she bent the elbow, that ulnar nerve kicked up over the epicondyle.” Id. at 1. Dr. Katarincic’s post-operative diagnosis was “left cubital tunnel with subluxation of ulnar nerve over the left medial epicondyle.” Pet. Ex. 17 at 16.

Petitioner followed up with Dr. Katarincic on June 23, 2016, for her post-operative visit. Pet. Ex. 14 at 1. Dr. Katarincic documented that petitioner was doing well and could go back to work full duty on July 1, 2016. Id. Petitioner’s right arm was tender at the cubital tunnel and she had a positive Tinel’s sign. Id.

On February 13, 2017, petitioner returned to Dr. Chopra stating she was doing much better and had decreased her pain medications. Pet. Ex. 18 at 1. She reported, however, that typing and holding a hair dryer in her right arm caused her pain. Id. Dr. Chopra’s diagnosis of right brachial plexus injury to the radial and ulnar nerve at the axilla remained unchanged. Id. at 2.

In December 2017, petitioner injured her shoulder lifting weights. Pet. Ex. 24 at 29; Pet. Ex. 26 at 32. On December 26, 2017, petitioner presented to Performance Physical Therapy reporting left shoulder pain “that started 2 weeks ago.” Pet. Ex. 26 at 32. From July 2018 through July 2019, petitioner sought treatment from physiatrist, Dr. Claudia Wheeler. Pet. Ex. 24 at 29-32; Pet. Ex. 27 at 2-4. Petitioner reported injuring her “left shoulder in December 2017,” and an MRI showed “subacromial bursitis and distal osteolysis.” Pet. Ex. 24 at 30. Physical examination revealed that petitioner had normal bilateral upper extremity strength (5/5), normal musculoskeletal exam, and no neurological abnormalities of the right arm. Id. at 32.

## **B. Expert Reports**

### **1. Petitioner – Dr. Pradeep Chopra**

#### **a. Background and Qualifications**

Dr. Pradeep Chopra began treating petitioner on August 6, 2015. Pet. Ex. 16 at 1. Dr. Chopra is Director of the Interventional Pain Management Center in Pawtucket, Rhode Island. Id. He is also a Clinical Assistant Professor in the Department of Medicine at Brown Medical School and is board certified in pain management. Id. Petitioner submitted one expert report authored by Dr. Chopra. Pet. Ex. 16.

#### **b. Opinion**

Although petitioner seeks compensation for alleged injuries to both her right and left arms, Dr. Chopra’s opinions appear to be limited to petitioner’s right arm, the arm in which she received the vaccination on October 2, 2014. In his expert report, he did not reference petitioner’s history, symptoms, diagnosis, or treatment of her non-vaccinated left arm.

In his report, Dr. Chopra first addressed the position of the petitioner at the time of vaccine administration. Prior to administering the vaccine, the nurse asked petitioner “to place her hand on her thigh with her right upper extremity medially rotated and abducted.” Pet. Ex. 16 at 1. The vaccine was then injected into the petitioner’s upper arm. Id. Petitioner “felt severe paresthesias in her arm that shot down [] to her fingers.” Id. Petitioner subsequently had an EMG, “significant for right ulnar neuropathy.” Id. Dr. Chopra performed a physical examination of the petitioner on August 6, 2015, which was significant for “dysesthesia to the right ulnar nerve distribution . . . and patchy areas of dysesthesia to the right deltoid . . . [and] right wrist and hand.” Id. Petitioner also had tightness in the muscles of her upper back (rhomboid and upper trapezius). Id.

Dr. Chopra opined that petitioner “developed symptoms of right brachial plexus injury to the radial and ulnar nerve at the upper arm.” Pet. Ex. 16 at 1. The “mechanism of injury” was direct injury to the ulnar and radial nerves from the needle used for vaccination. Id. He explained that

the needle used to administer the flu vaccine passed inferior to the humerus as the arm was placed in an abducted and internally rotated position and struck her ulnar nerve as it originated from the medial cord of the brachial plexus. It then proceeded deeper into the posterior cord of the brachial plexus which eventually becomes the radial nerve.

Id.

Dr. Chopra opined within a reasonable degree of medical certainty that the October 2, 2014 flu shot “clearly caused her injuries.” Pet. Ex. 16 at 1. The basis for his opinion was two-fold: (1) petitioner did not have any pre-existing pain in her arm prior to vaccination, and (2) she experienced “severe neuropathic pain” at the time of injection. Id. Dr. Chopra opined that petitioner would have symptoms of neuropathic pain for an indefinite period of time as neuropathic pain is “notoriously slow to resolve if at all.” Id. at 2.

While Dr. Chopra attributed petitioner’s ulnar and radial nerve injuries to her flu vaccination, he opined that petitioner’s cubital tunnel syndrome was not related to her vaccine injury. Pet. Ex. 16 at 1. He did not explain the reasons for this opinion.

## **2. Petitioner – Dr. Lawrence Steinman**

### **a. Background and Qualifications**

Dr. Lawrence Steinman received his B.A. from Dartmouth College and his M.D. from Harvard Medical School. Pet. Ex. 23-8 at 1. He then completed residencies in neurology and pediatrics at Stanford University. Id. He has worked as a professor of neurology and pediatrics at Stanford for the past thirty-nine years. Pet. Ex. 23 at 1. Dr. Steinman is board certified in neurology. Id. He has cared for hundreds of adults and children with various forms of injury to the brachial plexus, various forms of peripheral neuropathy, as well as various autoimmune neurologic conditions including diseases of the autonomic nervous system, central nervous system, and peripheral nervous system. Id. In 2015, Dr. Steinman received the Cerami Prize in Translational Research and published a scientific autobiography describing his research career studying the immune response to flu virus at Jonas Salk’s New Institute. Id. at 4. Dr. Steinman submitted two expert reports in this case. Pet. Exs. 23, 32.

### **b. Opinion**

#### **i. Diagnosis**

Dr. Steinman opined that as a result of her flu vaccination on October 2, 2014, petitioner sustained a “significant aggravation of an underlying previously asymptomatic ulnar

neuropathy,” which he also referred to as “cubital tunnel syndrome.” Pet. Ex. 23 at 1. Dr. Steinman did not specify which arm had this diagnosis.

Although Dr. Steinman opined that significant aggravation of a previously asymptomatic cubital tunnel syndrome was the proper diagnosis, the balance of his opinion was based on causation, not significant aggravation. His expert reports, reviewed as a whole, and in context with petitioner’s medical records, treating physician opinions, and clinical course, establish by preponderant evidence that but for petitioner’s vaccination, she would not have sustained right ulnar neuropathy.

**ii. Althen Prong One: Medical Theory of Causation**

Dr. Steinman’s medical theory is that acute injury to the ulnar nerve can occur due to “misguided injection into the deltoid.” Pet. Ex. 23 at 1, 7. In support of his opinion, Dr. Steinman cited an article by Kim et al., describing a review of scholarly databases for reports of upper extremity nerve injuries following intramuscular injection or venipuncture. Id. Based on the research, Kim et al. concluded that while upper limb nerve injury following injection is rare, it can occur.<sup>15</sup> Pet. Ex. 23.1 at 1.

Kim et al. identified the mechanisms by which nerve injuries occur due to injections. These include, “injection-related nerve injury; direct needle trauma; toxic effects of injected agents on nerve fibers and surrounding tissues; [and] nerve compression due to hematoma or edema.” Pet. Ex. 23.1 at 2. Of these, direct injury to a nerve from needle trauma was identified as the most common causal mechanism. Id.

Specifically related to ulnar nerve injury caused by injection, Dr. Steinman cited another article by Geiringer and Leonard, who reported two cases of vaccine injection ulnar nerve injury. Pet. Ex. 23.2. Both patients were administered vaccinations by the same nurse, who instructed the patients to “fixate their hands on the hips and rotate their arms.” Id. at 4. The vaccine was then “administered to patients’ sidearm while the nurse was standing at the patients’ side. Combining this position of arm rotation with a sidearm delivery facilitated administration on the medial-lying neurovascular bundle instead of the target deltoid muscle.” Pet. Ex. 23.1 at 4.

The first patient was a 24-year-old man who received a measles, mumps, and rubella (“MMR”) vaccination in the left upper arm, using a 5/8-inch needle. Pet. Ex. 23.2 at 1. He complained of numbness and paresthesias in his left fourth and fifth fingers within 30 minutes of vaccination, that worsened over the next two days. Id. Three days after vaccination, he developed “subtle weakness of the [] ulnar-innervated intrinsic hand muscles.” Id. He also had diminished sensation in the ulnar distribution of the fingers and wrist. Id.

The second patient was a 26-year-old female who received a Haptavax B vaccination using a one-inch needle in the left upper arm. Pet. Ex. 23.2 at 1. She had numbness of several

---

<sup>15</sup> Kim et al. estimated the annual incidence was 3.38 per 1 million intramuscular injections, of which 8% occurred in the arm. Pet. Ex. 23.1 at 2.

fingers several hours after vaccination that increased over the next 24 hours. Id. EMG performed one month later showed mild abnormalities in muscles of the forearm and hand. Id.

Dr. Steinman's opinions as to causation referenced petitioner's vaccinated arm (right arm). He did not offer a causation opinion related to petitioner's left arm. Specifically, Dr. Steinman did not address petitioner's assertion that to compensate for her injured right arm, she overused her left arm, resulting in injury.

### **iii. Althen Prong Two: Logical Sequence of Events**

Dr. Steinman's opinion as to Prong Two is premised on a "two hit" theory. Pet. Ex. 23 at 7. First, he noted that injury to the ulnar nerve can occur after injections into the deltoid, as supported by the medical literature cited above. Id. at 6. Here, Dr. Steinman opined that petitioner sustained an injury to her ulnar nerve from the flu vaccination (first hit), and that this injury "provoked chronic neuropathic pain from a previously asymptomatic cubital tunnel syndrome" (second hit). Id. at 7. These two hits "combined to provoke chronic pain and functional impairment." Id.

Put in other words, Dr. Steinman opined that the damage to the petitioner's ulnar nerve caused by vaccination, "unmasked neuropathology that had been dormant previously." Pet. Ex. 23 at 7. Dr. Steinman opined, "even if there existed an anatomic basis for the cubital tunnel syndrome, its clinical presentation had not been evident until immediately after the injection on Oct. 2, 2014. This represents a significant aggravation of a previously silent, subclinical cubital tunnel syndrome." Id. Dr. Steinman concluded that "the October 2, 2014 immunization more likely than not significantly aggravated an asymptomatic cubital tunnel syndrome. If not for the injury to the ulnar nerve upon immunization on October 2, 2014 the cubital tunnel syndrome would have remained dormant." Id.

To support his opinion as to Prong Two, Dr. Steinman noted that petitioner's symptoms were consistent with cubital tunnel syndrome. Pet. Ex. 23 at 4-5. She had altered sensation of the ring finger and little finger and her symptoms worsened with elbow flexion while sleeping. Id. at 4. She also reported hand weakness, pain along the posteromedial elbow, and "weakness of the ulnar innervated muscles (intrinsic muscles of the hand)." Id.

Dr. Steinman also reviewed petitioner's diagnostic testing. Pet. Ex. 23 at 5. Testing by nerve percussion at the retrocondylar groove reproduced pain and paresthesias. Id. Petitioner's EMGs showed decreased absolute conduction velocity at the level of the elbow consistent with ulnar neuropathy. Id. Testing also ruled out other causes of petitioner's symptoms, including radial neuropathy, median neuropathy, brachial plexopathy, thoracic outlet syndrome, or C8/T1 radiculopathy. Id. Dr. Steinman also opined that petitioner had no complaints of right shoulder, hand or arm complaints prior to her October 2, 2014 vaccination. Id. at 6. Petitioner's "severe pain and psychiatric issues related to her right shoulder, elbow, and hand as demonstrated repeatedly in the medical record" appear only after October 2, 2014. Id.

Dr. Steinman disagreed with respondent's expert, Dr. Chaudry, who opined that the vaccine injection site was appropriate and the deltoid muscle was not missed. Pet. Ex. 32 at 1.

Dr. Steinman agreed that two of petitioner’s treating physicians noted the injection appeared to be administered in the correct area of the deltoid, however, he stated, “[i]t’s entirely possible the injection could have looked proper to the naked eye. However, without the specific information about the strange positioning of the arm at the time of injection, it’s impossible for her doctors to tell whether the injection was administered properly.” Id. “Considering the position of the arm at the time of injection,” Dr. Steinman opined, “the needle [] penetrated the medial lying nerve bundle.” Id.

Further, Dr. Steinman emphasized that many of petitioner’s treating physicians suggested that she had a nerve injury from the flu vaccination. Pet. Ex. 32 at 2.

Dr. Steinman did not offer an opinion as to Althen Prong Two as it relates to petitioner’s left arm condition. He did not opine on a logical sequence of cause and effect as to how a vaccine administered in petitioner’s right arm, causing right ulnar injury, could cause left ulnar nerve injury.

**iv. Althen Prong Three: Proximate Temporal Relationship**

In support of his opinion that there was a proximate temporal relationship between vaccination and injury, Dr. Steinman cited the case report in Geiringer and Leonard, which illustrated an abrupt onset of numbness following immunization. Pet. Ex. 23 at 6. In Geiringer and Leonard, the patient who received the MMR vaccination had paresthesias and numbness in the fingers within 30 minutes, that worsened over the next 48 hours. Pet. Ex. 23.2 at 1. Subtle weakness of the hand muscles was noted in 72 hours. Id.

Dr. Steinman did not offer an opinion as to Althen Prong Three regarding petitioner’s left arm condition.

**3. Respondent – Dr. Vinay Chaudry**

**a. Background and Qualifications**

Dr. Vinay Chaudry is a Professor of Neurology at the Johns Hopkins University School of Medicine and Co-Director of the EMG Laboratory at Johns Hopkins Hospital. Resp. Ex. A at 1. He received his Bachelor of Medicine and Bachelor of Surgery from the All India Institute of Medical Sciences in New Delhi, India, in 1980. Resp. Ex. B at 1. Dr. Chaudry is board certified in neurology, neuromuscular diseases, electrodiagnostic medicine (nerve conduction and EMG), and clinical neurophysiology. Resp. Ex. A at 1. He has had an active clinical practice for the past twenty-five years and sees approximately 2,000 patients a year for problems related to peripheral nerve disease. Id. Dr. Chaudry is involved in clinical research and has published over 120 publications which include peer reviewed articles, reviews, and book chapters. Id. Dr. Chaudry submitted two expert reports in this case. Resp. Exs. A, G.

**b. Opinion**

**i. Diagnosis**

With regard to diagnosis, Dr. Chaudry noted petitioner's symptoms, signs, EMG findings, ultrasound examination, and response to treatment are all typical for ulnar neuropathy at the elbow called cubital tunnel syndrome. Resp. Ex. A at 5. Like Dr. Steinman, all of Dr. Chaudry's opinions appear to relate to petitioner's vaccinated arm (right arm).

In his review of the petitioner's medical chronology, Dr. Chaudry noted that on March 31, 2016, petitioner saw Dr. Katarincic for "bilateral ulnar neuropathies." Resp. Ex. A at 4. Dr. Chaudry further noted that Dr. Katarincic "performed ulnar nerve transposition surgery" during which petitioner was noted to have compression of the ulnar nerve. Id. However, Dr. Chaudry did not note that petitioner's surgery was performed on her left arm, not her vaccinated right arm.

**ii. Althen Prong One: Medical Theory of Causation**

Dr. Chaudry disagreed with Dr. Steinman that an injection in the deltoid region could cause ulnar neuropathy at the level of the elbow. Resp. Ex. A at 6. According to Dr. Chaudry, direct trauma by the needle in the upper arm cannot explain symptoms arising from the elbow. Id. Dr. Chaudry opined "an injection given in the right deltoid region cannot cause the ulnar nerve to be compressed at the elbow." Id.

Further, Dr. Chaudry did not believe that an indirect immune-related phenomenon could explain right ulnar neuropathy at the elbow caused by vaccine injection. Resp. Ex. A at 6. He opined that an immune effect would at least take 24-48 hours before symptoms began, and that even then, an immune response could not cause focal structural compromise of the ulnar nerve at the elbow. Id.

Although Dr. Chaudry conceded that there was a possibility that positioning at the time of injection could trigger an underlying and asymptomatic ulnar neuropathy at the elbow to become transiently symptomatic, he did not believe such a scenario would cause persistent ulnar neuropathy symptoms. Resp. Ex. A at 6-7.

In his first expert report, Dr. Chaudry appears to have erroneously believed that petitioner had right instead of left ulnar nerve surgery. See Resp. Ex. A at 4-5. Dr. Chaudry stated that petitioner had "[s]urgical submuscular transposition of the right ulnar nerve" on April 22, 2016, and he attributed the operative findings of compression and subluxation of the ulnar nerve to be on the right side. Id. at 5. The operative report clearly states that the surgery was done on the left ulnar nerve, not the right. See Pet. Ex. 21 at 1-2. This confusion is emphasized as he cited the Journal of Hand Surgery to support his position that compression of the ulnar nerve at the elbow, where the ulnar nerve is prone to subluxation, could not be caused by injection or positioning. Dr. Chaudry's right/left confusion carries over to his second expert report.<sup>16</sup> Resp. Exs. E, G. Based in part on this confusion, he concludes that "[l]eft ulnar neuropathy at the elbow could not have been related to injection or positioning." Resp. Ex. A at 7.

---

<sup>16</sup> J.J. O'Hara & J.H. Stone, Ulnar Nerve Compression at the Elbow Caused by a Prominent Medial Head of the Triceps and an Anconeus Epitrochlearis Muscle, 21B J. Hand Surgery 133 (1996).



### iii. Althen Prong Two: Logical Sequence of Events

Dr. Chaudry opined that direct trauma by the needle in the upper arm could not explain symptoms arising from the elbow. Resp. Ex. A at 6. Dr. Chaudry explained that several of petitioner's treating physicians documented that the injection site in the deltoid region was correct, and there was no evidence in the medical records of traumatic hematoma, swelling, redness, or bruising in the area of injection. Id. Because petitioner's ulnar neuropathy was localized to the elbow, as all her clinical findings suggest, Dr. Chaudry believed that Dr. Steinman's causation argument suggesting an injury in the arm is flawed. Resp. Ex. G at 1.

If ulnar nerve injury occurred in the upper arm and was caused by the flu vaccination, as purported to have occurred by Dr. Steinman, multiple medical examinations of the ulnar nerve would be expected to be abnormal. Resp. Ex. G at 2. Dr. Chaudry stated, "[u]lnar nerve injury should cause weakness in ulnar nerve distribution (intrinsic muscles/grip among others) and sensory loss in the fourth and fifth digits." Id. Dr. Chaudry asserted that petitioner showed normal ulnar nerve distribution findings, as noted by physician examinations performed by neurologists and hand surgeons. Id.

As for indirect immune-related trauma, Dr. Chaudry stated, petitioner's symptoms happened immediately, whereas an immune effect would at least take 24-48 hours to cause symptoms. Resp. Ex. A at 6. Petitioner's ulnar neuropathy was also clearly localizable to a known site of compression at the elbow and was documented by the surgeon to be "definitely compressed."<sup>17</sup> Id. Dr. Chaudry concluded that an immune response cannot cause focal structural compromise of the ulnar nerve at the elbow or cause an enlarged triceps muscle. Id.

As for the possibility that an underlying asymptomatic ulnar neuropathy at the elbow became symptomatic due to positioning at the time of injection, Dr. Chaudry stated this was unlikely due to the few seconds of elbow flexion positioning needed for giving the injection. Resp. Ex. A at 6-7.

Regarding causation posited by Dr. Chopra, Dr. Chaudry disagreed that the "flu vaccine needle passed inferior to the humerus, struck the ulnar nerve as it originated from the medial cord of the brachial plexus, and then the needle kept on going deeper into the posterior cord and damaged the radial nerve part of the brachial plexus." Resp. Ex. A at 8. Given the anatomy of the brachial plexus and the number of other structures in the axilla, Dr. Chaudry deemed that scenario unlikely. Id.; see Resp. Ex. F.<sup>18</sup> Citing an article that reviewed the anatomy of the brachial plexus in marmosets (species of monkeys), Dr. Chaudry opined it would be "almost impossible for the needle to penetrate the length of the deltoid muscle all the way down to the

---

<sup>17</sup> This statement is incorrect, as petitioner's ulnar surgery was on her left ulnar nerve. There is no evidence in the record to suggest that surgery was performed on her right ulnar nerve or that her surgeon observed compression of the right ulnar nerve.

<sup>18</sup> Kenji Emura et al., Anatomical Study of the Brachial Plexus in the Common Marmoset, 300 Anatomical Rec. 1299 (2017).

axilla and injure two nerves.” Resp. Ex. A at 8; see Resp. Ex. F. Further, Dr. Chaudry asserted that petitioner did not have symptoms of radial nerve injury, which is “characterized by loss of elbow, wrist, and finger extension, sensory loss in the distal extensor forearm, and loss of triceps reflex.” Resp. Ex. A at 7. Dr. Chaudry stated that petitioner was not diagnosed with a radial nerve injury by Dr. McGunigal, Dr. Graff, or Dr. McCloy. Id. He also noted that the EMGs did not demonstrate abnormalities of petitioner’s radial nerve. Id. at 8. Similarly, Dr. Chaudry opined that Dr. Chopra’s opinion that petitioner tight muscles in her upper back were related to vaccination was erroneous, as these abnormalities of the muscles, “cannot occur from ulnar or radial nerve injuries.” Id.

Dr. Chaudry concluded petitioner had the typical presentation of right ulnar nerve compression at the elbow from subluxation and triceps muscle enlargement that existed prior to the flu vaccine.<sup>19</sup> Resp. Ex. A at 8. To a reasonable degree of medical certainty, Dr. Chaudry opined, “[a]lthough it is possible that positioning during the injection, transiently causes paresthesias, the compressive neuropathy of the ulnar nerve was not causally related to the flu vaccine.” Id.

In his second expert report, Dr. Chaudry explained that he agreed with Dr. Steinman that petitioner had “ulnar neuropathy localized to the cubital tunnel at the elbow,” but disagreed that she also had an “ulnar injury at the level of the upper arm.” Resp. Ex. G at 1. Dr. Chaudry argued that petitioner’s ulnar neuropathy was “localized to the elbow” based on her “clinical findings, EMG findings, treatment strategies including surgery, and response to treatment confirmed this diagnosis. None of her clinical findings suggested an injury in the arm.”<sup>20</sup> Id. Further, Dr. Chaudry asserted that Dr. Steinman provided no reference to support his opinion that “the injection in the upper arm made an asymptomatic cubital tunnel at the elbow symptomatic.” Id. at 8.

As for petitioner’s left ulnar symptoms, Dr. Chaudry opined that “compression of [petitioner’s] left ulnar neuropathy at the elbow suggest[s] [petitioner’s] inherent vulnerability to compressive neuropathy” unrelated to right arm vaccination. Resp. Ex. A at 7. Dr. Chaudry opined that it is unlikely that petitioner’s left ulnar neuropathy at the elbow was related to injection or positioning of the right arm at the time of vaccination. Id.

#### **iv. Althen Prong Three: Proximate Temporal Relationship**

Dr. Chaudry did not offer an opinion as to the appropriateness of petitioner’s injury onset assuming a mechanism of direct trauma caused by administration (injection) of the vaccine. He did, however, opine that “an indirect immune related phenomenon . . . would at least take 24-48

---

<sup>19</sup> Again, Dr. Chaudry confuses the facts. The subluxation and triceps enlargement were noted during surgery on petitioner’s left arm, not the right.

<sup>20</sup> It is not clear here whether Dr. Chaudry is referring to petitioner’s ulnar neuropathy in her right or left arm, since he mentions surgery, which occurred in petitioner’s left non-vaccinated arm.

hours” before the onset of symptoms. Resp. Ex. A at 6. He implied that the indirect immune mechanism could not be at play here because petitioner’s symptoms began immediately.

## **VI. DISCUSSION**

### **A. Standard of Adjudication—Factual Issues**

A petitioner must prove, by a preponderance of the evidence, the factual circumstances surrounding her claim. § 13(a)(1)(A). To resolve factual issues, the special master must weigh the evidence presented, which may include contemporaneous medical records and testimony. See Burns v. Sec’y of Health & Hum. Servs., 3 F.3d 415, 417 (Fed. Cir. 1993) (explaining that a special master must decide what weight to give evidence including oral testimony and contemporaneous medical records). Contemporaneous medical records are presumed to be accurate. See Cucuras v. Sec’y of Health & Hum. Servs., 993 F.2d 1525, 1528 (Fed. Cir. 1993). To overcome the presumptive accuracy of medical records testimony, a petitioner may present testimony which is “consistent, clear, cogent, and compelling.” Sanchez v. Sec’y of Health & Hum. Servs., No. 11-0685V, 2013 WL 1880825, at \*3 (Fed. Cl. Spec. Mstr. Apr. 10, 2013) (citing Blustein v. Sec’y of Health & Hum. Servs., No. 90-2808V, 1998 WL 408611, at \*5 (Fed. Cl. Spec. Mstr. June 30, 1998)).

### **B. Standards for Adjudication—Causation**

The Vaccine Act was established to compensate vaccine-related injuries and deaths. § 10(a). “Congress designed the Vaccine Program to supplement the state law civil tort system as a simple, fair and expeditious means for compensating vaccine-related injured persons. The Program was established to award ‘vaccine-injured persons quickly, easily, and with certainty and generosity.’” Rooks v. Sec’y of Health & Hum. Servs., 35 Fed. Cl. 1, 7 (1996) (quoting H.R. Rep. No. 908 at 3, reprinted in 1986 U.S.C.C.A.N. at 6287, 6344).

Petitioner’s burden of proof is by a preponderance of the evidence. § 13(a)(1). The preponderance standard requires a petitioner to demonstrate that it is more likely than not that the vaccine at issue caused the injury. Moberly v. Sec’y of Health & Hum. Servs., 592 F.3d 1315, 1322 n.2 (Fed. Cir. 2010). Proof of medical certainty is not required. Bunting v. Sec’y of Health & Hum. Servs., 931 F.2d 867, 873 (Fed. Cir. 1991). In particular, petitioner must prove that the vaccine was “not only [the] but-for cause of the injury but also a substantial factor in bringing about the injury.” Moberly, 592 F.3d at 1321 (quoting Shyface v. Sec’y of Health & Hum. Servs., 165 F.3d 1344, 1352-53 (Fed. Cir. 1999)); see also Pafford v. Sec’y of Health & Hum. Servs., 451 F.3d 1352, 1355 (Fed. Cir. 2006). The received vaccine, however, need not be the predominant cause of the injury. Shyface, 165 F.3d at 1351. A petitioner who satisfies this burden is entitled to compensation unless respondent can prove, by a preponderance of the evidence, that the vaccinee’s injury is “due to factors unrelated to the administration of the vaccine.” § 13(a)(1)(B).

To receive compensation through the Program, petitioner must prove either (1) that she suffered a “Table Injury”—i.e., an injury listed on the Vaccine Injury Table—corresponding to a vaccine that she received, or (2) that she suffered an injury that was actually caused by a

vaccination. See §§ 13(a)(1)(A), 11(c)(1); Capizzano v. Sec’y of Health & Hum. Servs., 440 F.3d 1317, 1319-20 (Fed. Cir. 2006). Because petitioner’s claim predates the inclusion of SIRVA on the Table, she must prove her claim by showing that her injury was caused-in-fact by the vaccination in question. § 11(c)(1)(C)(ii). To do so, petitioner must establish, by preponderant evidence: “(1) a medical theory causally connecting the vaccination and the injury; (2) a logical sequence of cause and effect showing that the vaccination was the reason for the injury; and (3) a showing of a proximate temporal relationship between vaccination and injury.” Althen, 418 F.3d at 1278.

The causation theory must relate to the injury alleged. The petitioner must provide a sound and reliable medical or scientific explanation that pertains specifically to this case, although the explanation need only be “legally probable, not medically or scientifically certain.” Knudsen v. Sec’y of Health & Hum. Servs., 35 F.3d 543, 548-49 (Fed. Cir. 1994). Petitioner cannot establish entitlement to compensation based solely on her assertions; rather, a vaccine claim must be supported either by medical records or by the opinion of a medical doctor. § 13(a)(1). In determining whether petitioner is entitled to compensation, the special master shall consider all material in the record, including “any . . . conclusion, [or] medical judgment . . . which is contained in the record regarding . . . causation.” § 13(b)(1)(A). The undersigned must weigh the submitted evidence and the testimony of the parties’ proffered experts and rule in petitioner’s favor when the evidence weighs in her favor. See Moberly, 592 F.3d at 1325-26 (“Finders of fact are entitled—indeed, expected—to make determinations as to the reliability of the evidence presented to them and, if appropriate, as to the credibility of the persons presenting that evidence.”); Althen, 418 F.3d at 1280 (noting that “close calls” are resolved in petitioner’s favor).

### **C. Analysis of Factual Issues**

There are three factual issues to resolve: “a) the nature of petitioner’s right arm injury, including the diagnosis of her injury; b) the nature of petitioner’s left arm injury, including the diagnosis of her injury; and c) whether petitioner had a pre-existing cubital tunnel syndrome in her right and/or left arms prior to vaccination.” Joint Pre-Hearing Submissions at 1. For ease of discussion, these will be simplified into two sections, right (vaccinated) arm and left (non-vaccinated) arm.

#### **1. Petitioner’s Right Arm**

The undersigned finds that petitioner sustained an ulnar nerve injury following her flu vaccination. This finding is based on the medical records of petitioner’s treating physicians and the expert reports of Dr. Steinman and Dr. Chaudry.

A number of petitioner’s treating physicians diagnosed her with a right ulnar nerve injury. The day after vaccination, October 3, 2014, petitioner saw Dr. Sparhawk who diagnosed petitioner with “neuropraxia of upper extremity.” Pet. Ex. 20 at 61. On October 6, 2014, petitioner saw Dr. Littell, who diagnosed petitioner with neuropraxia and neuritis. On October 10, 2014, petitioner was evaluated by Dr. Schimmel, who questioned the possibility of whether petitioner had “inflammation around one of the nerves in the arm related to the flu shot.” Pet.

Ex. 2 at 7. Petitioner was seen by neurologist, Dr. Karaniasias, who diagnosed “right ulnar nerve neuropathy.” Pet. Ex. 3 at 5. Petitioner saw Dr. McGunigal on January 22, 2015, who conducted a physical examination, ultrasound and EMG testing, and diagnosed right ulnar neuropathy at the elbow at the retrocondylar groove. Pet. Ex. 19 at 4. Dr. Chopra also diagnosed petitioner with right ulnar neuritis. Pet. Ex. 8 at 3. In summary, five physicians evaluated petitioner and diagnosed her with an ulnar nerve injury. These physicians used the words irritation, irritability, inflammation, and neuritis to discuss the nature of the ulnar nerve injury.

Likewise, both Dr. Steinman and Dr. Chaudry opined that petitioner’s right arm diagnosis was ulnar neuropathy. See Pet. Ex. 23 at 1; Resp. Ex. A at 5. While Dr. Chaudry attributes the cause to non-vaccine factors, he does not dispute that petitioner’s symptoms, signs, EMG findings, ultrasound examination, and response to treatment are all typical for ulnar neuropathy at the elbow. Resp. Ex. A at 5.

Next, the undersigned finds that there is no evidence in the record to suggest that petitioner had pre-existing cubital tunnel syndrome in her right arm prior to vaccination. She did not have any complaints of pain, paresthesias, numbness, or other symptoms of right ulnar nerve pathology prior to vaccination. While Dr. Steinman opines that petitioner had an “underlying asymptomatic ulnar neuropathy,” he cites no facts from petitioner’s history or medical records to support this conclusion. Pet. Ex. 23 at 7. He cites no medical literature to explain his opinion. It is conjecture without foundation.

In conclusion, the record persuasively establishes that the proper diagnosis of the petitioner’s right arm condition is ulnar neuropathy. The record contains no evidence to suggest that petitioner had pre-existing cubital tunnel syndrome in her right arm.

## **2. Petitioner’s Left Arm**

The first reference in petitioner’s medical records to her left arm occurs one day post-vaccination, during an evaluation by Dr. Sparhawk. Dr. Sparhawk performed Tinel’s tests on both petitioner’s arms, and documented that the test was positive on the right arm, and that “Tinel’s on the left elbow reveals similar symptoms but much less intense.” Pet. Ex. 20 at 61. Other than the Tinel’s test referenced by Dr. Sparhawk, there is no evidence that petitioner had ever complained of any signs or symptoms of any nerve problem in her left arm. There is no evidence of prior arm pain, numbness, tingling, or weakness.

The first time petitioner was diagnosed with a left ulnar problem was when she had an IME by Dr. McCloy on June 10, 2015. He diagnosed “mild left ulnar neuropathy, not causally related to her vaccination.” Pet. Ex. 15 (part 2) at 163. Dr. McCloy opined that this condition had “no connection” with her vaccination. Id. at 164.

From August through November 2015, petitioner saw Dr. Chopra who assessed petitioner with “diffuse musculoskeletal pain” in her left arm due to “overuse.” Pet. Ex. 8 at 4. On September 10, 2015, Dr. Chopra opined that petitioner’s left arm pain was “a result of her repetitive strain injury since she is unable to use her right upper extremity.” Pet. Ex. 13 at 7. In

November, Dr. Chopra noted that petitioner's left arm was better after physical therapy. *Id.* at 1. Dr. Chopra did not diagnose petitioner with left ulnar neuropathy.

Dr. Katarincic diagnosed petitioner with bilateral ulnar neuropathies in March 2016. Petitioner had left ulnar nerve surgery in April 2016. In the operative note, Dr. Katarincic describes how petitioner's left ulnar nerve was being pushed over the epicondyle during elbow flexion. Postoperatively, Dr. Katarincic noted the diagnosis of "left cubital tunnel with subluxation of ulnar nerve over the left medial epicondyle." Pet. Ex. 21 at 1. Read in context, the operative note suggests that petitioner's ulnar nerve was subluxed, causing the symptoms that she was experiencing.

Neither Dr. Steinman nor Dr. Chaudry offer an opinion as to the diagnosis of petitioner's left arm.

The undersigned finds that based on the medical records of Dr. McCloy and Dr. Katarincic, petitioner was initially diagnosed with left sided ulnar neuropathy in June 2015, and underwent surgery in April 2016. Thus, the proper diagnosis relative to petitioner's left arm is left ulnar neuropathy.

The only early evidence of any abnormality of petitioner's left arm is the positive Tinel's test performed by Dr. Sparhawk the day after vaccination, October 3, 2015. However, Dr. Sparhawk did not make a diagnosis of left ulnar neuropathy. There has been no testimony or evidence proffered as to the significance of the Tinel's test. Thus, documentation of a positive Tinel's test, without more, is insufficient to establish the petitioner had a pre-existing condition in her left arm. Therefore, the undersigned finds that petitioner did not have pre-existing cubital tunnel syndrome in her left arm.

#### **D. Causation Analysis**

The parties dispute two issues: a) whether the flu vaccine administered to petitioner on October 2, 2014 caused her right arm injuries; and b) whether the flu vaccine administered to petitioner on October 2, 2014 caused her left arm injuries.

##### **1. Althen Prong One: Medical Theory of Causation**

The first causation question at issue is whether a flu vaccine administered by injection into a vaccinee's arm can cause ulnar neuropathy. Under Althen Prong One, petitioner must set forth a medical theory explaining how the received vaccine could have caused the sustained injury. Andreu v. Sec'y of Health & Hum. Servs., 569 F.3d 1367, 1379 (Fed. Cir. 2009); Pafford, 451 F.3d at 1355-56. Petitioner's theory of causation need not be medically or scientifically certain, but it must be informed by a "sound and reliable" medical or scientific explanation. Boatmon v. Sec'y of Health & Hum. Servs., 941 F.3d 1351, 1359 (Fed. Cir. 2019); see also Knudsen, 35 F.3d at 548; Veryzer v. Sec'y of Health & Hum. Servs., 98 Fed. Cl. 214, 223 (2011) (noting that special masters are bound by both § 13(b)(1) and Vaccine Rule 8(b)(1) to consider only evidence that is both "relevant" and "reliable"). If petitioner relies upon a medical opinion to support her theory, the basis for the opinion and the reliability of that basis must be

considered in the determination of how much weight to afford the offered opinion. See Broekelschen v. Sec’y of Health & Hum. Servs., 618 F.3d 1339, 1347 (Fed. Cir. 2010) (“The special master’s decision often times is based on the credibility of the experts and the relative persuasiveness of their competing theories.”); Perreira v. Sec’y of Health & Hum. Servs., 33 F.3d 1375, 1377 n.6 (Fed. Cir. 1994) (stating that an “expert opinion is no better than the soundness of the reasons supporting it” (citing Fehrs v. United States, 620 F.2d 255, 265 (Ct. Cl. 1980))).

Here, the undersigned finds petitioner has shown by preponderant evidence a sound and reliable theory that a flu vaccination administered intramuscularly can cause ulnar nerve injury and neuropathy, and therefore, petitioner has satisfied the first Althen prong. This finding is based on medical literature, published case reports, the petitioner’s medical records, and the opinions of petitioner’s treating opinions.

Petitioner’s theory, as proffered by Dr. Steinman, is that injury to the ulnar nerve can occur due to a misguided injection. This mechanism is supported by medical literature authored by Kim et al., Geiringer and Leonard, and Salanga and Hahn, which explains that ulnar nerve injuries can occur after injection, including intramuscular injections of vaccines, administered in the deltoid region of the upper arm. Kim et al. identified the mechanisms of injury to include direct needle trauma, toxic effects of vaccine ingredients on the nerve and adjacent tissues, and nerve compression due to bruising or inflammation. Of these, direct injury to the ulnar nerve caused by the needle was the most common causal mechanism.

Geiringer and Leonard describe two case reports where a nurse’s vaccine administration technique caused ulnar nerve injuries to two patients. The position of the patients’ arms, combined with a sidearm delivery, resulted in the needle hitting the nerve bundle on the medial side of the arm instead of the deltoid muscle. These reports illustrate that ulnar nerve injury can occur due to improper administration of a vaccine.

That vaccine administration can cause injury to the ulnar nerve appears to be established knowledge within the medical community, given the fact that several of petitioner’s treating physicians expressed an opinion that direct injury to the ulnar nerve can occur due to vaccination. Dr. Littell opined that the ulnar “nerve was irritated either by the [vaccine] needle or the liquid.” Pet. Ex. 20 at 32. Dr. Karaniasias suggested that positioning at the time of vaccination “could be the culprit.” Pet. Ex. 3 at 5. Dr. McGunigal noted that ulnar nerve injury had been reported following “misdirected intramuscular deltoid injections.” Pet. Ex. 19 at 1. These statements illustrate that the petitioner’s theory of misguided needle causing needle trauma is a not a novel theory, but a mechanism known by physicians.

For the above reasons, the undersigned finds that petitioner has established by preponderant evidence that a vaccine administered by injection into the upper arm can cause injury to the ulnar nerve to be a sound and reliable causal theory.

However, petitioner has not provided preponderant evidence of a sound and reliable causal theory to explain how ulnar neuropathy can occur in the non-vaccinated arm. Dr. Steinman did not offer a causal theory as to how a vaccination injected into the right arm can

cause ulnar neuropathy in the opposite arm. He did not address petitioner's contention that compensation for an injured arm can cause overuse and ulnar injury of the other arm. Other than several conclusory statements in some of the petitioner's medical records, there was no evidence offered to support this overuse theory. Petitioner offered no medical opinion, medical literature, case reports, or explanation of this theory relative to the left arm. As such, the undersigned finds that petitioner has failed to establish by preponderant evidence a sound and reliable medical theory for how injury can occur to the ulnar nerve of a non-vaccinated arm.

## 2. Althen Prong Two: Logical Sequence of Events

The second causation issue is whether the flu vaccine administered to petitioner on October 2, 2014, caused her to sustain right and/or left ulnar neuropathy. Under Althen Prong Two, petitioner must prove by a preponderance of the evidence that there is a "logical sequence of cause and effect showing that the vaccination was the reason for the injury." Capizzano, 440 F.3d at 1324 (quoting Althen, 418 F.3d at 1278). "Petitioner must show that the vaccine was the 'but for' cause of the harm . . . or in other words, that the vaccine was the 'reason for the injury.'" Pafford, 451 F.3d at 1356 (internal citations omitted).

In evaluating whether this prong is satisfied, the opinions and views of the vaccinee's treating physicians are entitled to some weight. Andreu, 569 F.3d at 1367; Capizzano, 440 F.3d at 1326 ("[M]edical records and medical opinion testimony are favored in vaccine cases, as treating physicians are likely to be in the best position to determine whether a 'logical sequence of cause and effect show[s] that the vaccination was the reason for the injury.'" (quoting Althen, 418 F.3d at 1280)). Medical records are generally viewed as trustworthy evidence, since they are created contemporaneously with the treatment of the vaccinee. Cucuras, 993 F.2d at 1528. The petitioner need not make a specific type of evidentiary showing, i.e., "epidemiologic studies, rechallenge, the presence of pathological markers or genetic predisposition, or general acceptance in the scientific or medical communities to establish a logical sequence of cause and effect." Capizzano, 440 F.3d at 1325. Instead, petitioner may satisfy her burden by presenting circumstantial evidence and reliable medical opinions. Id. at 1325-26.

With regard to the second Althen prong, the undersigned finds there is preponderant evidence to support a logical sequence of cause and effect showing the October 2, 2014 flu vaccination caused petitioner's right ulnar neuropathy. See Althen, 418 F.3d at 1278. This finding is based primarily on the records and opinions of petitioner's treating physicians.

Petitioner's medical records establish that the day after vaccination, October 3, 2014, petitioner saw Dr. Sparhawk, who diagnosed petitioner with "neuropaxia of upper extremity" and concluded that petitioner had "nerve root irritation as a result of the injection." Pet. Ex. 20 at 61. On October 6, 2014, petitioner saw Dr. Littell, who diagnosed petitioner with neuropaxia and neuritis. Dr. Littell concluded that petitioner's "nerve was irritated either by the needle or the liquid when she was given the flu shot." Id. at 32. October 10, 2014, petitioner was evaluated by Dr. Schimmel, who questioned the possibility of whether petitioner had "inflammation around one of the nerves in the arm related to the flu shot." Pet. Ex. 2 at 7. Petitioner was seen by neurologist, Dr. Karaniasias on December 4, 2014, who diagnosed petitioner with "right ulnar nerve neuropathy." Pet. Ex. 3 at 5. Dr. Karaniasias believed



petitioner's symptoms were caused by the "irritability of the nerve in its segment along the elbow" and he opined that positioning at the time of vaccination "could be the culprit." Pet. Ex. 3 at 5. Petitioner saw Dr. McGunigal on January 22, 2015, who diagnosed right ulnar neuropathy at the elbow and retrocondylar groove. Pet. Ex. 19 at 3. Subsequently, Dr. McGunigal noted that this type of injury had been reported following "misdirected intramuscular deltoid injections." *Id.* at 1. Finally, Dr. Chopra, opined that petitioner's flu shot "clearly caused her injuries." Pet. Ex. 16 at 1.

In summary, these treating physicians attributed petitioner's right ulnar nerve injury to nerve irritation, caused by either by the needle or the vaccine ingredients, the positioning at the time of vaccine injection, or to a misdirected intramuscular deltoid injection. Thus, five of petitioner's treating physicians offered opinions that support petitioner's causal theory.<sup>21</sup>

Further, there is no evidence to suggest that petitioner's right ulnar injury was caused by a factor unrelated to vaccination. She did not sustain any other trauma, other than vaccination, or have any prior or pre-existing injury to her right arm.

Additionally, the petitioner's clinical course is strikingly similar to the two cases reported by Geiringer and Leonard of injection related ulnar neuropathy.<sup>22</sup> "Case one" had paresthesias and numbness in his fourth and fifth fingers within 30 minutes of vaccination. Pet. Ex. 23.2 at 1. After petitioner received her flu vaccination by intramuscular injection in her right deltoid, she returned to employee health about 10 to 15 minutes later complaining of "numbness to her right pinky and tingling down the right elbow to the hand" on October 2, 2014. Pet. Ex. 1 at 1; Pet. Ex. 20 at 63.

Like the patients in Geiringer and Leonard, petitioner was asked to bend her right arm and place her hand on her hip, and flex her arm forward.<sup>23</sup> Following her vaccination, petitioner's employee health record confirms that she reported pain and numbness down her arm to her pinky finger. Petitioner's symptoms included pain, numbness, and mild sensory disturbance in the ulnar distribution, consistent with ulnar nerve symptoms reported in the medical literature. Petitioner underwent EMG testing, interpreted by Dr. McGunigal as diagnostic for right ulnar neuropathy.

---

<sup>21</sup> None of petitioner's treating physicians diagnosed her with pre-existing right ulnar neuropathy. Further, their opinions were not premised on significant aggravation of pre-existing ulnar neuropathy.

<sup>22</sup> The patients in these case reports did not have pre-existing ulnar neuropathy. Further, the authors opinions as to the mechanisms of causation were not premised on significant aggravation of any prior condition.

<sup>23</sup> Of note, the person who administered the petitioner's vaccination was instructed on the proper technique for vaccine administration following petitioner's adverse reaction. *See* Pet. Ex. 20 at 64.

For all of these reasons, the undersigned finds that petitioner has provided preponderant evidence of causation that her right ulnar neuropathy was caused by her flu vaccination.

However, petitioner has not shown by preponderant evidence that her left ulnar injury was caused by her flu vaccination administered in her right arm on October 2, 2014. The first reference in petitioner's medical records to her left arm occurs one day post-vaccination, during an evaluation by Dr. Sparhawk. Dr. Sparhawk performed Tinel's tests on both petitioner's arms, and documented that the test was positive on the right arm, and that "Tinel's on the left elbow reveals similar symptoms but much less intense." Pet. Ex. 20 at 61. Dr. Sparhawk did not document or describe the significance of the test result relative to the left side. Dr. Sparhawk made no diagnosis as to petitioner's left arm.

The first reference to petitioner's left arm symptoms appear in June 2015. On June 8, 2015, petitioner told her counselor, Peter Erickson, that her left arm hurt because she had been using it "in a compensatory manner." See Pet. Ex. 7 at 4. On June 10, 2015, petitioner was evaluated by Dr. McCloy for an IME, and he diagnosed "mild left ulnar neuropathy, not causally related to her vaccination." Pet. Ex. 15 (part 2) at 163. Dr. McCloy further opined that this condition had "no connection" with her vaccination. Id. at 164.

From August through November 2015, petitioner saw Dr. Chopra who documented that she had "diffuse musculoskeletal pain" in her left arm due to "overuse." Pet. Ex. 8 at 4. On September 10, 2015, Dr. Chopra noted that petitioner had left arm pain was "a result of her repetitive strain injury since she is unable to use her right upper extremity." Pet. Ex. 13 at 7. Although he did not explain what he meant by the words, "repetitive strain injury," when read in context with his note that petitioner had musculoskeletal pain, one thinks of a musculoskeletal type strain, not a nerve injury. Subsequently, in his expert report, Dr. Chopra opined that petitioner's diagnosis of cubital tunnel syndrome was not related to petitioner's vaccine injury.<sup>24</sup> See Pet. Ex. 16 at 1.

Dr. Katarincic diagnosed petitioner with bilateral ulnar neuropathies in March 2016, with "subluxation" on the left side. See Pet. Ex. 14 at 6. Dr. Katarincic performed left ulnar nerve surgery on petitioner in April 2016; petitioner's postoperative diagnosis was "left cubital tunnel syndrome with subluxation of the ulnar nerve over the left medial condyle." Pet. Ex. 21 at 1-2. There is nothing in any of Dr. Katarincic's records to suggest that petitioner's left ulnar injury was caused by vaccination.

---

<sup>24</sup> Dr. Chopra does not specify whether this opinion relates to the right or left arm, and thus, his opinion is confusing. If he was referencing the right arm, then his expert report does not address the left ulnar neuropathy. Assuming he was referencing the right arm, however, the opinion is inconsistent with his opinion that petitioner's left upper extremity neuropathic pain was caused by the flu vaccination.

In July 2018, petitioner reported to physiatrist Dr. Wheeler that she had arm pain from her vaccination, and that her “[right] arm was becoming sore from overuse.”<sup>25</sup> See Pet. Ex. 24 at 29. Dr. Wheeler offered no opinion about the as to whether petitioner’s left arm pain was caused by overuse due to vaccination in the opposite arm. Pet. Ex. 24 at 29-32.

Neither Dr. Steinman nor Dr. Chaudry offered an opinion as to the diagnosis or cause of any problem with petitioner’s left arm.

In summary, the record contains several entries where the petitioner reported that because of the injury to her right arm, she was overusing her left arm, causing pain in her left arm. However, statements made by the petitioner do not constitute medical evidence of causation. No physician opined that petitioner had left ulnar neuropathy caused by overuse of the left arm due to petitioner’s inability to use her right arm. The record is void of medical evidence to connect the left arm nerve pathology to the vaccination administered in petitioner’s right arm. Therefore, the undersigned finds that petitioner has failed to show by preponderant evidence that her vaccination caused any injury to her left arm.

### **3. Althen Prong Three: Proximate Temporal Relationship**

Althen Prong Three requires petitioner to establish a “proximate temporal relationship” between the vaccination and the injury alleged. Althen, 418 F.3d at 1281. That term has been equated to mean a “medically acceptable temporal relationship.” Id. The petitioner must offer “preponderant proof that the onset of symptoms occurred within a timeframe which, given the medical understanding of the disease’s etiology, it is medically acceptable to infer causation-in-fact.” De Bazan v. Sec’y of Health & Hum. Servs., 539 F.3d 1347, 1352 (Fed. Cir. 2008). The explanation for what is a medically acceptable time frame must also coincide with the theory of how the relevant vaccine can cause the injury alleged (under Althen Prong One). Id.; Koehn v. Sec’y of Health & Hum. Servs., 773 F.3d 1239, 1243 (Fed. Cir. 2014); Shapiro v. Sec’y of Health & Hum. Servs., 101 Fed. Cl. 532, 542 (2011), recons. den’d after remand, 105 Fed. Cl. 353 (2012), aff’d mem., 503 F. App’x 952 (Fed. Cir. 2013).

Based on medical records, affidavits, and a review of the record as a whole, the undersigned finds the onset of petitioner’s right arm pain occurred immediately upon vaccination or shortly thereafter, as reflected by the employee health service records. The timing of onset shows a proximate temporal relationship between vaccination and injury, and is consistent with the case reports of ulnar nerve injuries described after vaccination. The temporal association is appropriate given the mechanism of injury. Thus, petitioner has satisfied the third Althen prong for her right ulnar neuropathy.

Because the petitioner has failed to establish preponderant evidence to support Althen Prong One or Two for her left ulnar neuropathy, she has failed to establish preponderant evidence of causation. Additionally, petitioner has offered no evidence as to what the appropriate temporal association should be given her theory of left ulnar injury due to overuse

---

<sup>25</sup> Dr. Wheeler appears to have confused the left and right arm. Based on the medical records and affidavit of petitioner, Dr. Wheeler probably meant to say “left” arm.

caused by overcompensation. Because she has offered no evidence on this element of causation, the undersigned finds she has failed to prove Althen Prong Three as to her left arm injury.

#### **E. Standards for Adjudication—Significant Aggravation**

The elements of an off-Table significant aggravation case are set forth in Loving. See Loving v. Sec’y of Health & Hum. Servs., 86 Fed. Cl. 135, 142-44 (2009); see also W.C. v. Sec’y of Health & Hum. Servs., 704 F.3d 1352, 1357 (Fed. Cir. 2013) (holding that “the Loving case provides the correct framework for evaluating off-table significant aggravation claims”). The Loving court combined the Althen test, which defines off-Table causation cases, with a test from Whitecotton. Whitecotton v. Sec’y of Health & Hum. Servs., 17 F.3d 374 (Fed. Cir. 1994), rev’d sub nom., Shalala v. Whitecotton, 514 U.S. 268 (1995) (concerning on-Table significant aggravation cases). The resultant test has six components, which are:

(1) the person’s condition prior to administration of the vaccine, (2) the person’s current condition (or the condition following the vaccination if that is also pertinent), (3) whether the person’s current condition constitutes a ‘significant aggravation’ of the person’s condition prior to vaccination, (4) a medical theory causally connecting such a significant worsened condition to the vaccination, (5) a logical sequence of cause and effect showing that the vaccination was the reason for the significant aggravation, and (6) a showing of a proximate temporal relationship between the vaccination and the significant aggravation.

Loving, 86 Fed. Cl. at 144.

The statute defines “significant aggravation” as “any change for the worse in a pre-existing condition which results in markedly greater disability, pain, or illness accompanied by substantial deterioration in health.” § 33(4). Here, petitioner has failed to show that she had pre-existing ulnar neuropathy. Thus, she is unable to show significant aggravation of her prior condition. Petitioner’s theory of causation, as explained by her treating physicians, Dr. Steinman, and the medical literature, are not premised on any underlying pre-existing neuropathy or significant aggravation. Instead, petitioner has presented a causation theory, that but for her flu vaccination, she would not have sustained injury to her right ulnar nerve. Under the facts and circumstances unique to this case, petitioner need not invoke a theory based on significant aggravation to show that she is entitled to compensation.

As for her left arm, petitioner has failed to prove Althen Prongs One, Two, and Three. These three prongs constitute three of the six elements necessary to establish significant aggravation (elements four through six). Therefore, petitioner’s claim for significant aggravation as to her left arm also fails.

#### **VII. CONCLUSION**

The undersigned finds there is preponderant evidence to satisfy all three Althen prongs and to establish that petitioner’s October 2, 2014 flu vaccination caused her right ulnar injury, and thus, she is entitled to compensation for that injury.

Petitioner has failed to establish by preponderant evidence that her left ulnar injury is compensable.

A separate damages order will issue.

**IT IS SO ORDERED.**

**s/Nora Beth Dorsey**  
Nora Beth Dorsey  
Special Master